

Earn
2 CE credits
This course was
written for dentists,
dental hygienists,
and assistants.

Restoration of an Immediate Extraction Site Using a High Silica Quartz Glass Fiber Reinforced Provisional Bridge

A Peer-Reviewed Publication
Written by Ian Shuman DDS, MAGD, AFAAID

Abstract

Following the extraction of a tooth it is frequently ideal to replace it at the same appointment. In instances where a multi-unit fixed prosthesis is the best treatment, an immediate provisional should be fabricated. Due to the length of time needed for the socket to heal completely and achieve its mature contour, a long term provisional must be created. This course will demonstrate the steps needed to fabricate a long term provisional bridge using a quartz fiber reinforcement material.

Educational Objectives

At the conclusion of this educational activity participants will be able to:

1. Discuss the need for a long term provisional bridge and understand the need for fiber reinforcement
2. Describe the materials and steps needed to create this temporary prosthesis
3. Restore an immediate extraction site with a fiber reinforced provisional bridge using the materials outlined with the steps discussed

Author Profile

Ian Shuman DDS, MAGD, AFAAID maintains a full-time general, reconstructive, and aesthetic dental practice in Pasadena, Maryland. Since 1995 Dr. Shuman has lectured and published on advanced, minimally invasive techniques. He has taught these procedures to thousands of dentists and developed many of the methods. Dr. Shuman has published numerous articles on topics including adhesive resin dentistry, minimally invasive restorative, cosmetic and implant dentistry. He is a Master of the Academy of General Dentistry, an Associate Fellow of the American Academy of Implant Dentistry, a Fellow of the Pierre Fauchard Academy. Dr. Shuman was named one of the Top Clinicians in Continuing Education since 2005, by Dentistry Today.

Author Disclosure

Dr. Ian Shuman has no commercial ties with the sponsors or the providers of the unrestricted educational grant for this course.

Go Green, Go Online to take your course

Publication date: Sept. 2014
Expiration date: Aug. 2017

Supplement to PennWell Publications

PennWell is an ADA CERP recognized provider. ADA CERP is a service of the American Dental Association to assist dental professionals in identifying quality providers of continuing dental education. ADA CERP does not approve or endorse individual courses or instructors, nor does it imply acceptance of credit hours by boards of dentistry.

Concerns or complaints about a CE provider may be directed to the provider or to ADA CERP at www.ada.org/goto/ce/p.

PennWell designates this activity for 2 continuing educational credits.

Dental Board of California: Provider 4527, course registration number CA# 02-4527-14081
"This course meets the Dental Board of California's requirements for 2 units of continuing education."

The PennWell Corporation is designated as an Approved PACE Program Provider by the Academy of General Dentistry. The formal continuing dental education programs of this program provider are accepted by the AGD for Fellowship, Mastership and membership maintenance credit. Approval does not imply acceptance by a state or provincial board of dentistry or AGD endorsement. The current term of approval extends from (11/1/2011) to (10/31/2015) Provider ID# 320452.

PennWell®

dental
CE
digest

ineedCE.com
The Academy of Dental
Therapeutics and Stomatology®

ADA CERP® | Continuing Education
Recognition Program

Academy
of General Dentistry®
PACE
Program Approval for
Continuing Education

This educational activity has been made possible through an unrestricted grant from RTD USA LLC.

This course was written for dentists, dental hygienists and assistants, from novice to skilled.

Educational Methods: This course is a self-instructional journal and web activity.

Provider Disclosure: PennWell does not have a leadership position or a commercial interest in any products or services discussed or shared in this educational activity nor with the commercial supporter. No manufacturer or third party has had any input into the development of course content.

Requirements for Successful Completion: To obtain 2 CE credits for this educational activity you must pay the required fee, review the material, complete the course evaluation and obtain a score of at least 70%.

CE Planner Disclosure: Heather Hodges, CE Coordinator does not have a leadership or commercial interest with products or services discussed in this educational activity. Heather can be reached at hhodges@pennwell.com

Educational Disclaimer: Completing a single continuing education course does not provide enough information to result in the participant being an expert in the field related to the course topic. It is a combination of many educational courses and clinical experience that allows the participant to develop skills and expertise.

Image Authenticity Statement: The images in this educational activity have not been altered.

Scientific Integrity Statement: Information shared in this CE course is developed from clinical research and represents the most current information available from evidence based dentistry.

Known Benefits and Limitations of the Data: The information presented in this educational activity is derived from the data and information contained in reference section. The research data is extensive and provides direct benefit to the patient and improvements in oral health.

Registration: The cost of this CE course is \$49.00 for 2 CE credits.

Cancellation/Refund Policy: Any participant who is not 100% satisfied with this course can request a full refund by contacting PennWell in writing.

Educational Objectives

At the conclusion of this educational activity participants will be able to:

1. Discuss the need for a long term provisional bridge and understand the need for fiber reinforcement
2. Describe the materials and steps needed to create this temporary prosthesis
3. Restore an immediate extraction site with a fiber reinforced provisional bridge using the materials outlined with the steps discussed

Abstract

Following the extraction of a tooth it is frequently ideal to replace it at the same appointment. In instances where a multi-unit fixed prosthesis is the best treatment, an immediate provisional should be fabricated. Due to the length of time needed for the socket to heal completely and achieve its mature contour, a long term provisional must be created. This course will demonstrate the steps needed to fabricate a long term provisional bridge using a quartz fiber reinforcement material.

Introduction

Following tooth extraction, there are a variety of methods available for immediate tooth replacement. Choices include implants, full and partial coverage fixed prostheses and removable partial dentures. Regardless of the selected modality, the periodontium will require a healing period prior to delivering the final restoration. To replace the missing tooth at the time of extraction, a long term provisional fixed prosthesis can be placed.

Discussion

In the past, provisional bridges have been fabricated with a variety of reinforcing materials including; acrylic with cast metal,¹ resin composite and orthodontic wire,² composite and post,³ both prefabricated⁴ and chairside fiber reinforced composite,⁵⁻⁹ among others.

Irrespective of the method used, “when placed immediately after an extraction, the provisional serves as a protective covering over the extraction site, helping prevent debris and contaminants from entering the surgical wound.¹⁰ This allows the surgically altered tissues time to fully mature in preparation for the definitive fixed prosthesis. It also maintains the pontic space and allows the occlusion to remain stable and in harmony. However, provisionals made of composite or acrylic alone are known to fracture and deteriorate over long periods of time and therefore, strengthening them using a fiber reinforcement material is the key to the long term success of these restorations. The clinical study below used a quartz fiber (Quartz Splint[®], RTD) to reinforce the long term provisional.

Fiber: Materials and Properties

There are several types of fiber reinforcement materials available including; polyethylene (Ribbond[®], Ribbond Products), E-Glass (everStick[®] C&B, StickTech Ltd.), fiberglass (F-Splint-Aid[®], Polydentia), and quartz glass (Quartz Splint[®], RTD). They have replaced metal for a variety of reasons including; strength-to-weight ratios, non-corrosive biocompatibility properties, excellent bonding properties, ease of repair, and economic, convenient chairside use.¹¹ In addition, properties such as ease of handling, retention and esthetics make these ideal resources for chairside treatment.

In a study evaluating the shear bond strength to enamel and flexural strength of different fiber-reinforced composites, Juloski et al. determined that [“the use of reinforcing fibers in combination with flowable composite is beneficial for enhanced resistance to flexural loads. Moreover, the flexural strength of fiber-reinforced composites is influenced by fiber composition and pattern.”]¹²

Ultimately, the proof of material superiority is the length of time they enhance the structural integrity of the devices into which they are embedded. In a study measuring the survival rates of resin bonded, glass fiber-reinforced composite fixed partial dentures, Vallittu showed a functional survival rate of 93% after rebonding or repairing with a mean survival time of 55 months.¹³ Other studies have shown an astonishing five-year survival rate of 3 unit fiber-reinforced composite fixed partial dentures.¹⁴

To maximize longevity, selecting the correct fiber product is crucial as there is a wide variation between products including; flexural strength, rigidity, architecture, surface treatment and methods used for incorporating polymeric resin. Also, there are significant differences in the chairside techniques required for handling and processing.

Quartz Fiber: Prosthetic Reinforcement

There is a considerable body of research on the topic of using quartz fibers to reinforce a wide variety of dental prostheses. A study by Berthold et al. demonstrated that quartz fiber splints offer superior rigidity and flexure compared with wire-composite splints.¹⁵ Yapp and Powers evaluated the flexural strength and modulus of the splinting materials previously mentioned. They found that quartz splints were the strongest and stiffest of the four materials with a flexural strength and modulus of 631 MPa and 24.0 GPa respectively.¹⁶ This was nearly a 40% increase over the other materials studied.

The Challenge

The challenge is to fabricate the provisional restoration directly without contaminating the surgical site as well as curing the fiber reinforced provisional material itself. Ideally, a method of temporization prior to extraction allows for direct fabrication in a bloodless field, preventing contamination of the provisional material itself. The following case demon-

strates the ease with which a fixed provisional restoration can be fabricated directly in the mouth using the patient's pre-existing occlusal pattern and tooth morphology without contaminating the socket or surgical site. In addition, this technique employs a method whereby the provisional is further strengthened using a high silica quartz fiber reinforcement material, allowing it to function for many months during the healing phase.

Case Report

The patient, a 45-year-old female presented with a history of pain when chewing in the upper left premolar area. Examination revealed that the upper left second premolar had root canal therapy, with a stainless steel post, core and crown (Figure 1). Due to non-restorable caries it was determined that the tooth be extracted and the site restored. The patient did not want an implant; therefore the most ideal treatment plan would be a traditional fixed prosthesis from the first premolar to first molar.

The patient was appointed and the site anesthetized. The temporization technique for this case employed the use of a posterior triple tray. An impression was made of the preoperative site using a polyvinyl siloxane impression material. The interproximal areas of the impression were opened up using college pliers (Figure 2). This was followed by removal of the crowns, core restoration and preparation of the abutment molar and premolar. The remaining coronal structure of the second premolar was reduced down to the gingivo-alveolar area with a concave shaped preparation made in the pulpal floor (Figure 3). This was created in order to mimic the gingival aspect of the future pontic shape following extraction. Prior to extraction of the tooth, the long term 3 unit fiber-reinforced provisional could now be fabricated directly in the mouth in a bloodless environment.

Quartz splint materials are available in various fiber architectures (unidirectional, woven, braided rope, mesh, etc). Each has properties and contents that allow for a wide range of mechanical and handling characteristics in fiber reinforced composites. Although the unidirectional splint material could have been used in this case, the woven quartz splint material was easier to manipulate and shape for this type of procedure. The appropriate amount of ready-to-use fibers are selected, measured and cut to length (Figure 4).

An auto-cure bis-acryl composite temporary restorative material was dispensed into the intaglio of the triple tray impression and the woven quartz splint fiber gently submerged into the uncured composite (Figures 5, 6). The quartz splint material used in this case is pre-wetted at the factory. This feature offers enhanced accuracy, convenience, consistency and quality.

The filled triple tray was seated to place intraorally and the patient was instructed to close into occlusion. Following the 2 minute setting time, the triple tray containing the

Figure 1.

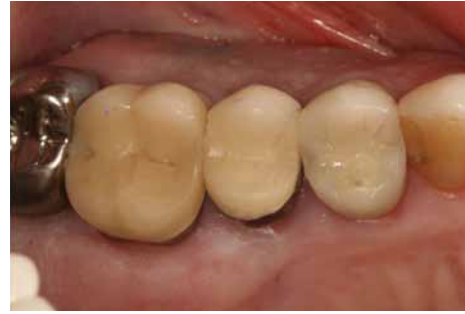

Figure 2.

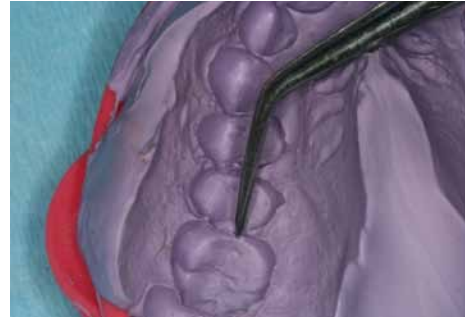


Figure 3.

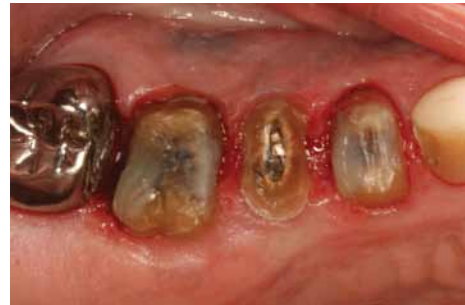

Figure 4.

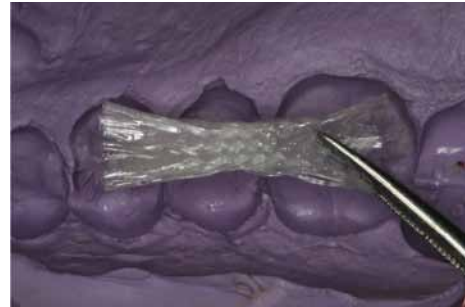
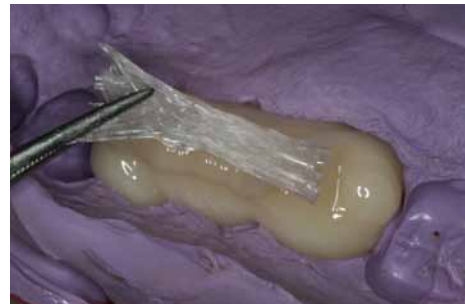
Figure 5.



temporary bridge was removed (Figure 7). Note that the woven quartz splint became invisible once incorporated into the cured bis-acryl material (Figures 8, 9). Following trimming, (Figures 10,11) the provisional was tried in the mouth and the fit evaluated. The occlusion was checked, adjusted as needed and polished. At this point, the root of the upper left second premolar was extracted (Figure 12). The socket

Figure 6.

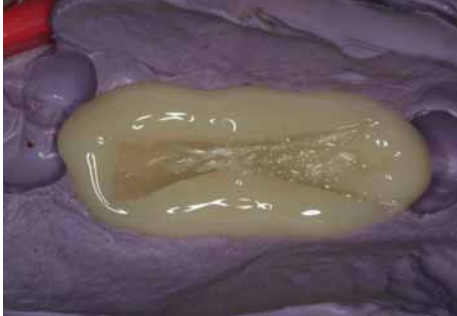

Figure 7.

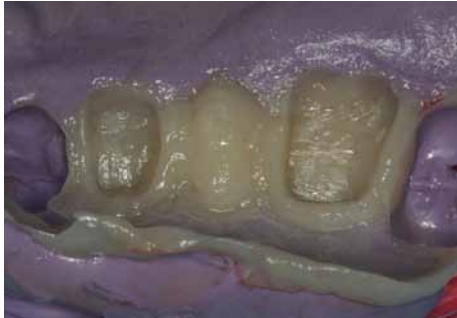

Figure 8.

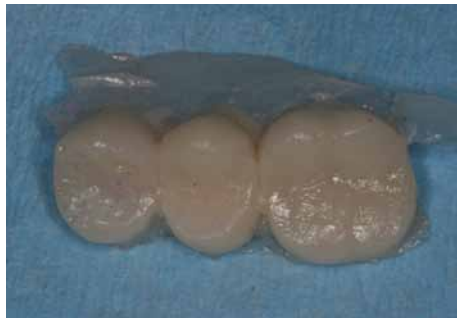
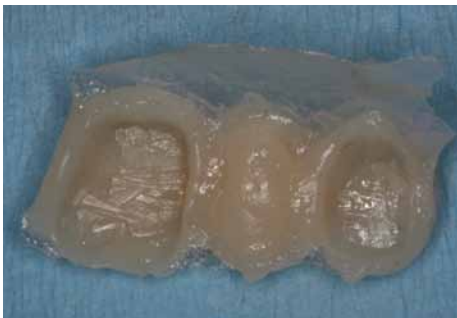
Figure 9.



was debrided, filled with a resorbable hemostatic sponge and sutured with 4.0 chromic gut (Figure 13). The quartz glass reinforced provisional restoration was luted with temporary cement (Figure 14). Several months later, the patient was seen for evaluation of the site and for enhancement of the pontic as needed (Figure 15).

Figure 10.

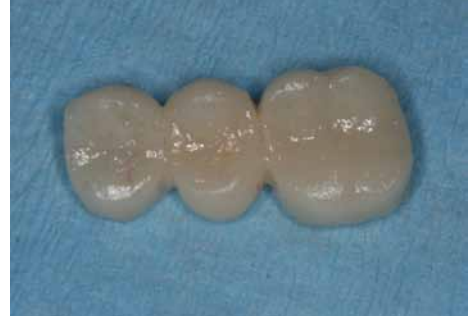

Figure 11.

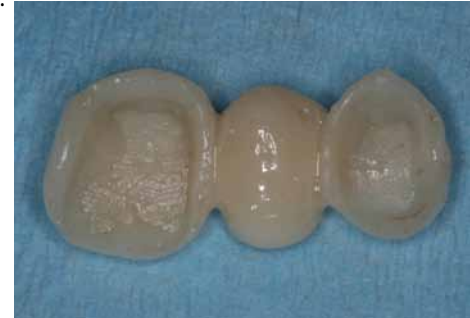

Figure 12.

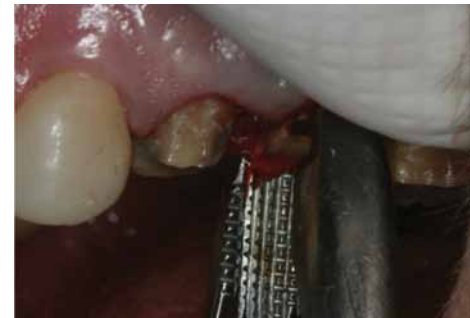

Figure 13.

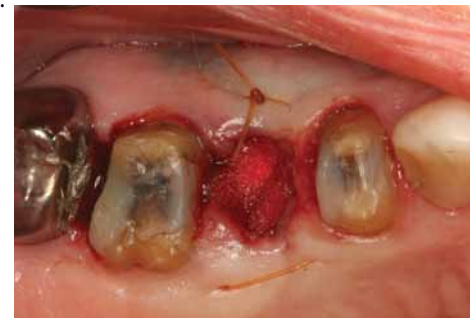

Figure 14.

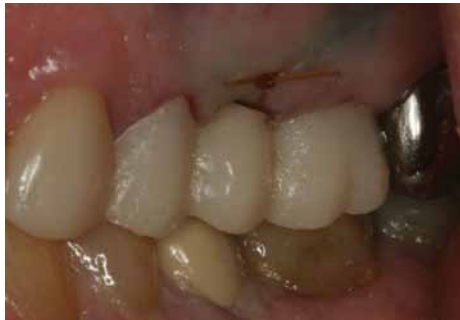
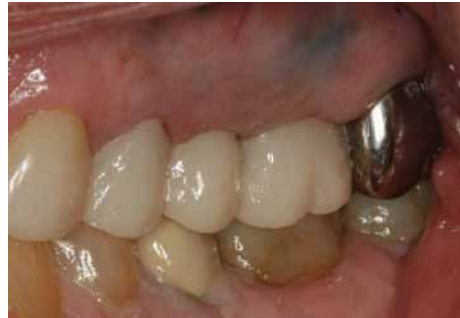
Figure 15.



Conclusion

While clinical performance is still the final determinant of success, flexure is still the most widely reported mechanical property, and test results are useful in developing and selecting new materials for clinical use and for comparing products.

It has been demonstrated that the use of a well-formed provisional restoration offers the ability to maintain oral health and promote healing of a surgical site. Using the technique of a fiber-reinforced, directly fabricated provisional restoration prior to extraction is a simple, elegant way to provide this type of care. The technique demonstrated in this case report is simple, reliable and repeatable.

Bibliography

1. Processed acrylic resin provisional restoration with lingual cast metal framework. Emtiaz S, Tarnow DP. *J Prosthet Dent* 1998;79:484-488.
2. The reinforced natural tooth pontic. Breault LG, Manga RK, Elliston NK. *Gen Dent*. 1997 Sep-Oct;45(5):474-6.
3. Effect of reinforcement methods on the retention of resin-bonded fixed partial dentures using a composite denture tooth as a pontic: in vitro evaluation. Minesaki Y, Suzuki S, Kajihara H, Tanaka T. *J Adhes Dent*. 2003 Fall;5(3):225-34
4. Single-tooth replacement with a chairside prefabricated fiber-reinforced resin composite bridge: a case study. Artega S, Meiers JC. *Gen Dent*. 2004 Nov-Dec;52(6):517-9.
5. Chairside prefabricated fiber-reinforced resin composite fixed partial dentures. Meiers JC, Freilich MA. *Quintessence Int*. 2001 Feb; 32(2): 99-104.
6. Composite-bonded bridges reinforced with Ribbond THM ribbon: an alternative of choice to other temporary

prosthetic methods. Thiam A, Djeredou KB, N'Dindin AC, Treil B, Kamagate FS, Calas P. *Odontostomatol Trop*. 2003 Dec; 26(104):7-13.

7. Anterior fiber-reinforced composite resin bridge: a case report. Chafaie A1, Portier R. *Pediatr Dent*. 2004 Nov-Dec;26(6):530-4.
8. Replacement of a maxillary central incisor using a polyethylene fiber-reinforced composite resin fixed partial denture: a clinical report Turker SB1, Sener ID. *J Prosthet Dent*. 2008 Oct;100(4):254-8.
9. Directly fabricated inlay-retained glass- and polyethylene fiber-reinforced composite fixed dental prostheses in posterior single missing teeth: a short-term clinical observation. Izgi AD1, Eskimez S, Kale E, Değer Y. *J Adhes Dent*. 2011 Aug;13(4):383-91.
10. Long-term provisionalization following tooth extraction. An innovative approach. Shuman IE. *Dent Today*. 2003 Jun;22(6):60-3
11. Fiber - reinforced composites in clinical dentistry. Freilich, MA, Meiers, JC, Duncan, JP, Goldberg, AJ. Quintessence Publishing, 2000.
12. Shear bond strength to enamel and flexural strength of different fiber-reinforced composites. Juloski J, Beloica M, Goracci C, Chieffi N, Giovannetti A, Vichi A, Vulicevic ZR, Ferrari M. *J Adhes Dent*. 2013 Apr;15(2):123-30.
13. Survival rates of resin-bonded, glass fiber-reinforced composite fixed partial dentures with a mean follow-up of 42 months: a pilot study. Vallittu PK. *J Prosthet Dent*. 2004 Mar;91(3):241-6.
14. Five-year survival of 3-unit fiber-reinforced composite fixed partial dentures in the anterior area. van Heumen CC, van Dijken JW, Tanner J, Pikaar R, Lassila LV, Creugers NH, Vallittu PK, Kreulen CM. *Dent Mater*. 2009 Jun;25(6):820-7.
15. Rigidity evaluation of quartz-fiber splints compared with wire-composite splints. Berthold C, Auer FJ, Potapov S, Petschelt A. *Dent Traumatol*. 2012 Feb;28(1):65-74.
16. Flexural Strength and Modulus of Several Splinting Products Yapp R, Powers J.M., THE DENTAL ADVISOR NUMBER 38 - JULY 2011

Author profile

Ian Shuman DDS, MAGD, AFAAID maintains a full-time general, reconstructive, and aesthetic dental practice in Pasadena, Maryland. Since 1995 Dr. Shuman has lectured and published on advanced, minimally invasive techniques. He has taught these procedures to thousands of dentists and developed many of the methods. Dr. Shuman has published numerous articles on topics including adhesive resin dentistry, minimally invasive restorative, cosmetic and implant dentistry. He is a Master of the Academy of General Dentistry, an Associate Fellow of the American Academy of Implant Dentistry, a Fellow of the Pierre Fauchard Academy. Dr. Shuman was named one of the Top Clinicians in Continuing Education since 2005, by *Dentistry Today*.

Author Disclosure

Dr. Ian Shuman has no commercial ties with the sponsors or the providers of the unrestricted educational grant for this course.

Online Completion

Use this page to review the questions and answers. Return to www.ineedce.com and sign in. If you have not previously purchased the program select it from the "Online Courses" listing and complete the online purchase. Once purchased the exam will be added to your Archives page where a Take Exam link will be provided. Click on the "Take Exam" link, complete all the program questions and submit your answers. An immediate grade report will be provided and upon receiving a passing grade your "Verification Form" will be provided immediately for viewing and/or printing. Verification Forms can be viewed and/or printed anytime in the future by returning to the site, sign in and return to your Archives Page.

Questions

- Following tooth extraction, the choices for immediate tooth replacement include all of the following except:
 - Implants
 - Full coverage fixed prostheses
 - Partial coverage fixed prostheses
 - Trans-periodontal crown
- Which of the following reinforcing materials have been used with provisional bridges?
 - Fiber-reinforced composite
 - Resin composite and orthodontic wire
 - Acrylic with cast metal
 - All of the above
- Which of the following serves as a protective covering over an extraction site?
 - Gelatin matrix
 - Provisional restoration
 - Sutures
 - Gauze pad
- Which of the following reinforcement materials is the key to the success of long term provisionals?
 - Cast metal
 - Nickel titanium wire
 - Fiber
 - Metal mesh
- The clinical case study used which type of fiber?
 - E-Glass
 - Polyethylene
 - Quartz
 - Fiberglass
- Fiber has replaced metal as a reinforcement material for all of the following except:
 - Biocompatibility
 - Corrosiveness
 - Strength-to-weight ratios
 - Ease of repair
- Which of the following conducted a study evaluating shear bond strength to enamel and flexural strength of different fiber-reinforced composites?
 - Stacey
 - Samson
 - Juloski
 - Edward
- Research has demonstrated survival rates for 3 unit fiber-reinforced composite fixed partial dentures as long as:
 - 2 years
 - 3 years
 - 5 months
 - 5 years
- Variations in the properties of fiber products include:
 - Architecture
 - Rigidity
 - Flexural strength
 - All of the above
- Ideally, a method of temporization prior to extraction allows for:
 - Direct fabrication in a bloody field
 - Preventing contamination of the provisional restoration
 - Direct fabrication in a contaminated field
 - None of the above
- When fabricating a direct provisional restoration the challenge is to avoid contaminating the:
 - Cured provisional
 - Surgical site
 - Uncured provisional
 - All of the above
- Which of the following preparation shapes was provided for the tooth to be extracted?
 - Convex
 - Concave
 - Oblong
 - None of the above
- Immediate placement of a provisional restoration provides:
 - Adequate time for healing
 - Maintenance of pontic space
 - Stable occlusion
 - All of the above
- Provisional restorations made only of composite or acrylic:
 - Have the same strength as reinforced provisionals
 - Have the same longevity as reinforced provisionals
 - Are more time consuming to fabricate than reinforced provisionals
 - None of the above
- In a study measuring the survival rates of resin bonded, glass fiber-reinforced composite fixed partial dentures, which of the following showed a functional survival rate of 93% after rebonding or repairing?
 - Vallittu
 - Anthony
 - Faird
 - Fries
- In the clinical case discussed, what type of bis-acryl composite temporary restorative material was used?
 - Light cure
 - Dual cure
 - Auto cure
 - None of the above
- Once incorporated into the cured bis-acryl material, the woven quartz splint material became:
 - Invisible
 - Visible
 - Opaque
 - Bioluminescent
- Pre-wetting the quartz splint at the manufacture level provides which of the following properties?
 - Accuracy
 - Convenience
 - Quality
 - All of the above
- A study by Berthold demonstrated that quartz-fiber splints offer superior rigidity and flexure compared with splints made from:
 - Composite alone
 - Non-precious alloy
 - Wire-composite
 - Ceramic mesh
- When placed immediately after an extraction, the provisional restoration:
 - Serves as a protective covering
 - Helps protect the extraction site from debris
 - Both a and b
 - None of the above

Restoration of an Immediate Extraction Site Using a High Silica Quartz Glass Fiber Reinforced Provisional Bridge

Name: _____ Title: _____ Specialty: _____

Address: _____ E-mail: _____

City: _____ State: _____ ZIP: _____ Country: _____

Telephone: Home () _____ Office () _____

Lic. Renewal Date: _____ AGD Member ID: _____

Requirements for successful completion of the course and to obtain dental continuing education credits: 1) Read the entire course. 2) Complete all information above. 3) Complete answer sheets in either pen or pencil. 4) Mark only one answer for each question. 5) A score of 70% on this test will earn you 2 CE credits. 6) Complete the Course Evaluation below. 7) Make check payable to PennWell Corp. **For Questions Call 216.398.7822**

Educational Objectives

1. Discuss the need for a long-term provisional bridge and understand the need for fiber reinforcement
2. Describe the materials and steps needed to create this temporary prosthesis
3. Have the ability to restore an immediate extraction site with a fiber reinforced provisional bridge using the materials outlined with the steps discussed

Course Evaluation

1. Were the individual course objectives met?

Objective #1: Yes No Objective #2: Yes No

Objective #3: Yes No

Please evaluate this course by responding to the following statements, using a scale of Excellent = 5 to Poor = 0.

- | | | | | | | |
|---|-------|-----|----|---|---|---|
| 2. To what extent were the course objectives accomplished overall? | 5 | 4 | 3 | 2 | 1 | 0 |
| 3. Please rate your personal mastery of the course objectives. | 5 | 4 | 3 | 2 | 1 | 0 |
| 4. How would you rate the objectives and educational methods? | 5 | 4 | 3 | 2 | 1 | 0 |
| 5. How do you rate the author's grasp of the topic? | 5 | 4 | 3 | 2 | 1 | 0 |
| 6. Please rate the instructor's effectiveness. | 5 | 4 | 3 | 2 | 1 | 0 |
| 7. Was the overall administration of the course effective? | 5 | 4 | 3 | 2 | 1 | 0 |
| 8. Please rate the usefulness and clinical applicability of this course. | 5 | 4 | 3 | 2 | 1 | 0 |
| 9. Please rate the usefulness of the supplemental webliography. | 5 | 4 | 3 | 2 | 1 | 0 |
| 10. Do you feel that the references were adequate? | | Yes | No | | | |
| 11. Would you participate in a similar program on a different topic? | | Yes | No | | | |
| 12. If any of the continuing education questions were unclear or ambiguous, please list them. | _____ | | | | | |
| 13. Was there any subject matter you found confusing? Please describe. | _____ | | | | | |
| 14. How long did it take you to complete this course? | _____ | | | | | |
| 15. What additional continuing dental education topics would you like to see? | _____ | | | | | |

If not taking online, mail completed answer sheet to
Academy of Dental Therapeutics and Stomatology,
 A Division of PennWell Corp.
 P.O. Box 116, Chesterland, OH 44026
 or fax to: (440) 845-3447

For IMMEDIATE results,
 go to www.ineedce.com to take tests online.
 Answer sheets can be faxed with credit card payment to
 (440) 845-3447, (216) 398-7922, or (216) 255-6619.

Payment of \$49.00 is enclosed.
(Checks and credit cards are accepted.)

If paying by credit card, please complete the following: MC Visa AmEx Discover
 Acct. Number: _____
 Exp. Date: _____

Charges on your statement will show up as PennWell

1. (A) (B) (C) (D)
2. (A) (B) (C) (D)
3. (A) (B) (C) (D)
4. (A) (B) (C) (D)
5. (A) (B) (C) (D)
6. (A) (B) (C) (D)
7. (A) (B) (C) (D)
8. (A) (B) (C) (D)
9. (A) (B) (C) (D)
10. (A) (B) (C) (D)
11. (A) (B) (C) (D)
12. (A) (B) (C) (D)
13. (A) (B) (C) (D)
14. (A) (B) (C) (D)
15. (A) (B) (C) (D)
16. (A) (B) (C) (D)
17. (A) (B) (C) (D)
18. (A) (B) (C) (D)
19. (A) (B) (C) (D)
20. (A) (B) (C) (D)

AGD Code 695

PLEASE PHOTOCOPY ANSWER SHEET FOR ADDITIONAL PARTICIPANTS.

COURSE EVALUATION and PARTICIPANT FEEDBACK
 We encourage participant feedback pertaining to all courses. Please be sure to complete the survey included with the course. Please e-mail all questions to: lhodges@pennwell.com.

INSTRUCTIONS
 All questions should have only one answer. Grading of this examination is done manually. Participants will receive confirmation of passing by receipt of a verification form. Verification of Participation forms will be mailed within two weeks after taking an examination.

COURSE CREDITS/COST
 All participants scoring at least 70% on the examination will receive a verification form verifying 2 CE credits. The formal continuing education program of this sponsor is accepted by the AGD for Fellowship/Mastership credit. Please contact PennWell for current term of acceptance. Participants are urged to contact their state dental boards for continuing education requirements. PennWell is a California Provider. The California Provider number is 4527. The cost for courses ranges from \$20.00 to \$110.00.

PROVIDER INFORMATION
 PennWell is an ADA CERP Recognized Provider. ADA CERP is a service of the American Dental Association to assist dental professionals in identifying quality providers of continuing dental education. ADA CERP does not approve or endorse individual courses or instructors, nor does it imply acceptance of credit hours by boards of dentistry.
 Concerns or complaints about a CE Provider may be directed to the provider or to ADA CERP at www.ada.org/cotocerp/.

RECORD KEEPING
 PennWell maintains records of your successful completion of any exam for a minimum of six years. Please contact our offices for a copy of your continuing education credits report. This report, which will list all credits earned to date, will be generated and mailed to you within five business days of receipt.

CANCELLATION/REFUND POLICY
 Any participant who is not 100% satisfied with this course can request a full refund by contacting PennWell in writing.

IMAGE AUTHENTICITY
 The images provided and included in this course have not been altered.

© 2014 by the Academy of Dental Therapeutics and Stomatology, a division of PennWell

COMPLETING A SINGLE CONTINUING EDUCATION COURSE DOES NOT PROVIDE ENOUGH INFORMATION TO GIVE THE PARTICIPANT THE FEELING THAT S/HE IS AN EXPERT IN THE FIELD RELATED TO THE COURSE TOPIC. IT IS A COMBINATION OF MANY EDUCATIONAL COURSES AND CLINICAL EXPERIENCE THAT ALLOWS THE PARTICIPANT TO DEVELOP SKILLS AND EXPERTISE.